

Pathobiology and transmission of the novel avian influenza A H7N9 virus isolated from humans in Muscovy ducks (*Cairina moschata*), European quail (*Coturnix coturnix*) and SPF chickens (*Gallus gallus domesticus*)

B. VIDAÑA^{1,2*}, R. DOLZ², N. BUSQUETS², A. RAMIS^{1,2}, R. RIVAS², R. VALLE², I. CORDÓN,² D. SOLANES², J. MARTÍNEZ MARTÍNEZ^{1,2} y N. MAJÓ^{1,2}

¹Departament de Sanitat i Anatomia Animals, ²Centre de Recerca en Sanitat Animal (CRESA), UAB-IRTA, Campus de la Universitat Autònoma de Barcelona, 08193 Bellaterra (Cerdanyola del Vallès), España.

*E-mail: beatriz.vidana@cresa.uab.cat

En aves, el virus H7N9 muestra baja patogenicidad, pero en humanos es causante de infecciones respiratorias graves con altas tasas de mortalidad. Este estudio evalúa la dinámica infectiva del virus de influenza aviar H7N9 de origen humano en tres especies aviarias comúnmente comercializadas en avicultura (codorniz, pollo y pato) y que presentan una distinta proporción de receptores para virus de influenza de origen aviar o mamífero en la cavidad nasal. Veinticinco animales de cada especie se dividieron en dos grupos de infección (A y B) con diez animales cada uno por especie. Todos los animales fueron inoculados con 10⁵ EID₅₀ del virus A/Anhui/1/2013(H7N9) aislado en humano en China. Para cada especie se evaluaron la excreción y transmisión viral a partir del muestreo de hisopos orofaríngeos, cloacales, pulpa de pluma y agua a diferentes tiempos post inoculación (pi). Además, los animales fueron sacrificados a diferentes tiempos pi para el estudio histopatológico y de distribución vírica por inmunohistoquímica. Finalmente, todos los animales supervivientes se testaron para la detección de anticuerpos mediante un ELISA comercial. Ninguna especie aviar mostró síntomas clínicos. Las codornices, y en menor grado los pollos, mostraron lesiones microscópicas caracterizadas por diferentes grados de sinusitis, rinitis y traqueítis. Todas las codornices inoculadas y contactos se infectaron presentando excreción viral, la cual fue más elevada en hisopos orofaríngeos que en cloacales. En menor medida, los pollos inoculados mostraron excreción viral detectada mayormente en hisopos orofaríngeos y el virus fue solamente transmitido a un animal contacto. La mayoría de los patos inoculados mostraron excreción viral en hisopos cloacales u orofaríngeos aunque a niveles menores que pollos y codornices. Tres de los cuatro patos contactos mostraron además excreción viral a día 3 post contacto. Todas las codornices presentaron anticuerpos frente al virus a día 14 pi, sin embargo, sólo un pato infectado y un pato contacto fueron positivos por ELISA. En este estudio se demuestra el importante papel de las especies aviarias, especialmente la codorniz, como reservorios y transmisores del virus H7N9 de origen humano. Es importante destacar el cuadro asintomático en estas especies aviarias y la necesidad de establecer planes de vigilancia para su control.

Palabras claves: Influenza aviar; avicultura; H7N9; transmisión; patobiología; patos; codornices; pollos

The new H7N9 virus shows low pathogenicity in avian species but human infections can cause severe illness with high rates of mortality, as a result of a severe respiratory failure. This study

evaluates the infection dynamics of a human H7N9 isolate in three commonly commercialized avian species (Chicken, quail and Muscovy ducks) which express different types of influenza virus host receptors (mammal or avian) throughout their upper respiratory tract. Twenty-five animals of each species were divided into experimental groups. All animals were inoculated with 10^5 EID₅₀ of the human isolate virus A/Anhui/1/2013(H7N9). For each species; morbidity, viral shedding and transmission were evaluated through sampling of oropharyngeal (OS) and cloacal swabs (CS), feather pulp (FP) and drinking water at different times post infection (dpi). Furthermore, pathological and immunohistochemical studies were performed. At 14 dpi, all surviving animals were tested for Influenza A virus IAV antibody detection by ELISA. No avian specie showed clinical signs or macroscopic lesions. Quail, and to a lesser extent chickens presented minor histopathological lesions, characterized by mild to moderate sinusitis, rhinitis and tracheitis. In general viral shedding was higher in OS than in CS in all the studied species. All infected and contact quail showed viral shedding in OS and/or CS at some point post infection. All infected chickens presented viral shedding in OS but only one contact chicken showed viral shedding at CS. Most infected Muscovy ducks showed viral secretion though at lower levels than quail and chicken. In addition, half of the contact Muscovy ducks presented viral shedding in OS and CS at different dpi. All quail, as well as, 1 infected and 1 contact duck seroconverted at 14 dpi. In this study, we showed that all the studied poultry species are potential reservoirs and vectors of H7N9 virus, especially quail and to a lesser extent chicken and Muscovy ducks. In the case of H7N9 surveillance, OS swab testing would be the choice tool for successful virus detection. It is important to point out the asymptomatic course of infection in these species, making essential the establishment of H7N9 surveillance for its control.

Keywords: Avian Influenza; poultry; H7N9; transmission; pathobiology; ducks; chickens; quails

Introduction

The emergence of novel influenza strains from the avian reservoir remains a constant threat to human and animal health. In March 2013, several individuals in China were reported to be infected with an avian A (H7N9) virus (Gao et al. 2013) and transmission from poultry to humans was confirmed by phylogenetic analyses (Liu J. et al. 2014).

Analysis from several H7N9 human isolates indicates that H7N9 is a reassorted virus incorporating envelope genes from an H7N3 avian strain and neuraminidase (NA) from an avian-adapted H7N9 Eurasian lineage strain with the internal genes from at least two H9N2 avian-adapted influenza strains commonly found in chickens (Liu D. et al. 2013).

In the past, transmission of H7 viruses from birds to mammals has been only rarely reported (Kwon et al. 2010). The H7N9 virus has only been detected in relatively low rates in avian species where it shows little virulence (Lam et al. 2013). However, human H7N9 virus infections can cause severe illness, characterized by a respiratory failure and acute respiratory distress syndrome (ARDS) (Yu et al. 2013). Since the emergence of the epidemic, 450 human cases have been reported, including 146 deaths; yet no strong evidence of human –to –human transmission has been reported (ECDC, Threat report 2014).

The SA-binding site in the hemagglutinin (HA) protein is a major determinant of the virus “host jump”. Human influenza viruses predominantly bind to $\alpha 2,6$ sialic acid (SA) host receptors expressed in the human respiratory tract while avian influenza viruses predominantly bind to $\alpha 2,3$ SA receptors. Recently, epidemiological data has linked H7N9 transmission to humans who have been exposed to birds in live markets (Lam et al. 2013) and studies focused on the H7N9 viral receptor binding shift elucidated that human H7N9 recognizes both avian and human receptor analogs (Liu et al. 2014, Shi et al. 2013). However, it is not clear which species of birds are most likely to be infected, or shed sufficient levels of virus to infect humans. Here, we evaluated the pathogenicity and transmissibility of an H7N9 human isolate in different commercial avian species, which present varying distribution of $\alpha 2,6$ and $\alpha 2,3$ SA receptors throughout the respiratory tract.

Materials and methods

Virus and animals

The A/Anhui/1/2013 (H7N9) strain was isolated from a patient during the 2013 H7N9 outbreak (van Riel et al. 2013). The virus was passaged at least 3 times in specific pathogen free (SPF) chicken eggs from the original patient sample and virus stocks were produced. Subsequently, the mean embryo infectious dose (EID₅₀) was determined. European quail (1 month old), Moscovy ducks (11 days) and SPF chickens (14 days) were used in this study. All animals were placed in negative pressure isolators under BSL-3 containment conditions after having been kept for one week of acclimatisation in the facilities. Animals were fed and water was provided *ad libitum* throughout the experiment. Before the infection, serum samples of all quail and ducks were confirmed to be seronegative for avian Influenza virus (AIV) by a competition ELISA test. Furthermore, oropharyngeal (OS) and cloacal (CS) swabs of 5 quail and 5 ducks were ensured to be negative for AIV by real time RT-PCR (RRT-qPCR).

Experimental design

Twenty-five animals of each species were randomly split into two groups with twenty challenged birds/group and one control group with 5 birds. For each group birds were subdivided into two experimental groups (A and B), each containing 10 animals. Each A group was used to evaluate morbidity, transmissibility, and viral shedding patterns and each group B was used for pathological studies. All animals in challenged groups were inoculated intranasally with 10⁵ EID₅₀ of H7N9 in a volume of 0.05 mL, except four birds of each A group which were used as contact animals and placed 24 hours after inoculation of animals. Control birds were inoculated intranasally with saline solution.

Sampling

All birds were monitored daily for clinical signs. OS and OC samples were obtained every day until 8 dpi and at 10, and 12 dpi in all animals belonging to the A groups in order to measure viral shedding by RRT-qPCR. Drinking water was collected at the same time points, and it was changed on a daily basis. In addition, OS samples were collected in duplicate at 3, 8 and 14 dpi for genetic characterization. In addition, feather pulp (FP) samples were obtained for viral detection by RRT-qPCR every day until 8 dpi, and then at 10 dpi.

Concurrently, at 1, 3, 5, 8 and 14 dpi, 2 animals from each B group and 1 animal from each control group were euthanized and necropsied for macro and microscopic evaluation. At 14 dpi, blood samples were collected before euthanasia in animals belonging to A groups (inoculated and contacts) to detect antibodies against AIV by a commercial ELISA (nom i casa comercial del kit).

Pathologic examination and immunohistochemical testing

Necropsies and tissue sampling were performed according to standard protocols. Brain, trachea, nasal turbinates, lung, heart, skin, thymus, bursa of Fabricius, liver, kidney, adrenal gland, gonad, duodenum, jejunum-ileum, cecum/cecal tonsil, colon, rectum and pancreas were taken for histological examination and stained with haematoxylin and eosin (HE) for inspection under light microscopy.

For the detection and distribution of AIV antigen by immunohistochemistry (IHC), the trachea, nasal turbinate, lung, duodenum, jejunum-ileum, cecum/cecal tonsil, colon, rectum and pancreas were stained with a primary antibody against the influenza A nucleoprotein as previously described (Bertran et al. 2013).

Viral RNA detection by RRT-qPCR

Viral RNA from OS, CS, FP, and drinking water samples was extracted with NucleoSpin® RNA Virus Kit (Macherey-Nagel, Düren, Germany) following the manufacturer's instructions. The resulting viral RNA extracts were tested by a TaqMan one-step quantitative RT-PCR as previously described by (Busquets et al. 2010).

Results and Discussion

AIV represents a major economic and health problem, not only for avian species but also for mammals and of course, humans (Capua et al. 2006). The emergence of the new H7N9 virus is of major concern, given that it shows little virulence in birds but can cause severe illness in humans (Gao et al. 2013, Yang et al. 2013). Here, we evaluated the pathobiology of a human H7N9 viral isolate in 3 different avian species commonly commercialized (chickens, quail and Muscovy ducks). In this experiment, none of the inoculated and contact animals presented any clinical sign or macroscopic lesion throughout the experimental infection. Microscopic lesions were restricted to the upper-respiratory tract of quail and chickens and were consistent with low-pathogenic AIV infection in these species (Bertran et al. 2013, Costa et al. 2012). In general, quail presented more severe histopathological lesions than chickens and were characterized by a mild to moderate lymphocytic rhinitis and sinusitis that in quail lasted from 1 to 8 dpi and in chicken from 1 to 5 dpi. In addition, inoculated quails also presented lymphocytic tracheitis at 5 dpi, confirming that quail are more susceptible to H7N9 infection as has been previously suggested (Pantin-Jackwood et al. 2014).

In accordance with the histopathological findings, quails presented the higher detection of AIV antigen which was mainly observed in nasal turbinates from 1 to 5 dpi and in the trachea at 5 dpi. In contrast, challenged chickens only presented AIV antigen in scarce epithelial cells in the nasal turbinate at 3 and 5 dpi. Muscovy ducks did not present any histopathological lesion or detection of AIV antigen in any organ examined. However, half of the infected and contact ducks presented viral oropharyngeal shedding throughout the experiment at low-level (Figure 1).

Viral shedding was also observed in quails and chickens, and results have been represented in Figure 1. Quail presented the higher levels of viral shedding replication in the upper respiratory tract followed by chickens and Muscovy ducks. Viral shedding was observed in OS and CS of most inoculated and in OS of most contact quail. Interestingly, most infected and all contact quail also showed low viral load at FP at 4 dpi and at 9 days post contact (dpc) respectively, indicating systemic dissemination in this species.

Of challenged SPF chickens, around half of the infected animals presented viral excretion in OS at different times post infection but viral secretion in CS and viral detection in FP was only observed in 1 chicken at 5 dpi. Besides, only 1 contact chicken presented viral shedding in CS at 4 dpc in contrast to contact Muscovy ducks which showed viral shedding in CS and OS from 3 to 11 dpc, despite chickens resulted more susceptible to H7N9 disease. All quails and 2 ducks (1 inoculated and 1 contact) seroconverted at 14 dpi. In general, viral shedding was much higher in the upper respiratory tract than in digestive system in all avian species studied. This was expected taking into account that poultry-adapted AIVs are normally highly shed in the respiratory tract in poultry (Marche et al. 2012, Mundt et al. 2009).

The constant AIV outbreaks detected around the world in poultry and humans possess a significant economic threat to poultry industry, and to public health (Liu J. et al. 2014). The emergence of H7N9 virus subtype is a major global concern, given that it has led to severe infection and mortality in humans, but shows no clinical disease in avian species (Watanabe et al. 2013). The host restriction of influenza A viruses is determined by specific sialic acid receptors in the upper respiratory tract. Ducks have mainly $\alpha 2,3$ receptors, quail possess mainly $\alpha 2,6$ receptors and chickens possess both $\alpha 2,3$ and $\alpha 2,6$ SA receptors (Costa et al. 2012). Effective viral transmission from inoculated animals to naïve contact quail and Muscovy ducks has been confirmed, even though the original host was human. These findings suggest either quick H7N9 virus adaptation, or that adaptation may not be needed for H7N9 to replicate and be transmitted between human and avian species, confirming the substantial role of commercial avian species in H7N9 epidemiology. Of particular interest are the results observed in Muscovy ducks, which presented viral shedding and efficient transmission to contact animals, despite not presenting any clinical signs, or histopathological lesions.

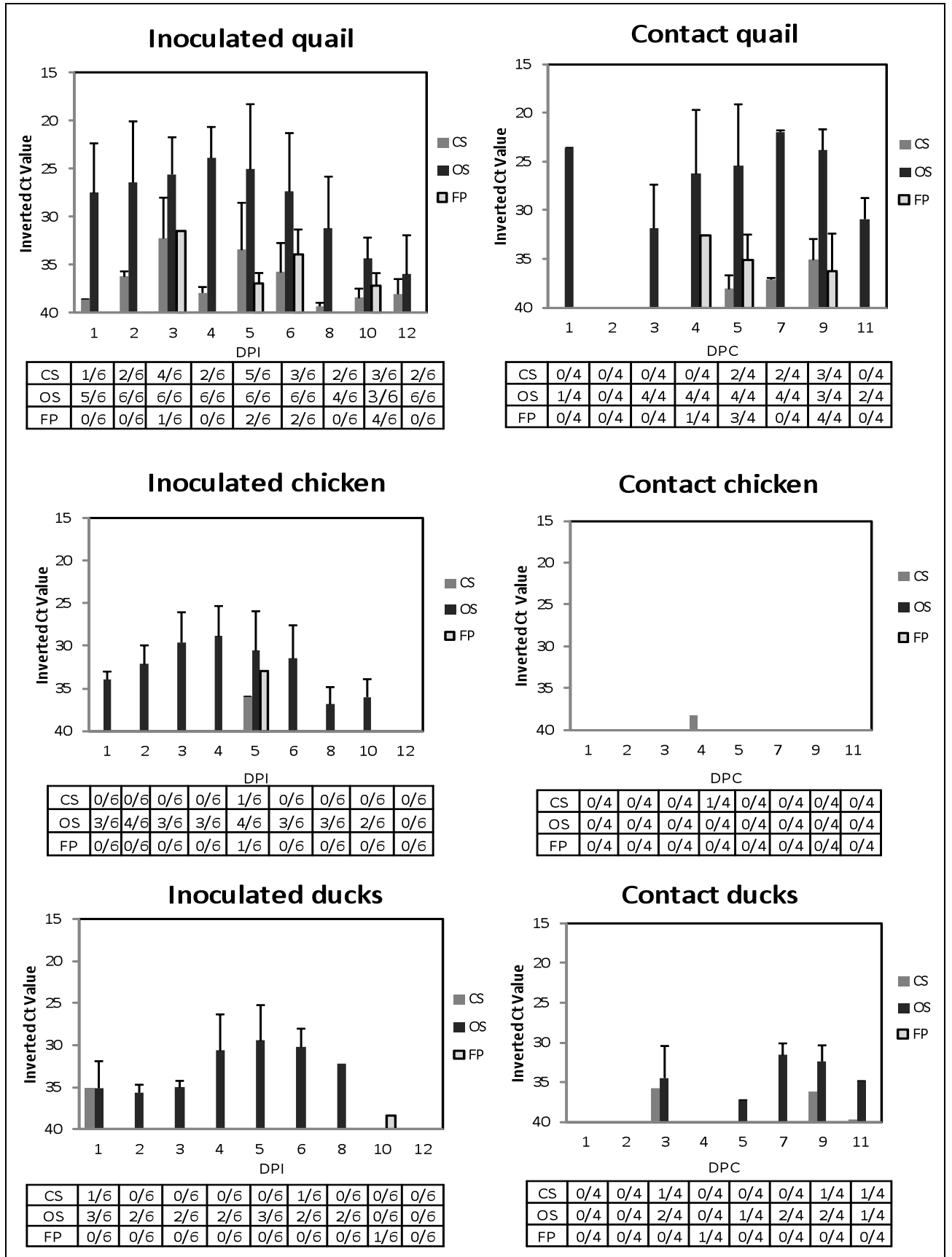


Figure 1: Viral RNA shedding detected by RRT-qPCR in animals experimentally challenged with human isolated H7N9 virus. (DPI) days post inoculation, (DPC) days post contact.

On the contrary, chickens showed low transmission rate, in spite the fact that infected chickens presented high viral secretions, were susceptible to H7N9 disease and express both α 2,3 and α 2,6 receptors in their respiratory tract. Recently, It has been shown that H7N9 isolate recognized both α 2,6 and α 2,3 receptor analogs (Liu J. et al. 2014, Shi et al. 2013), nevertheless the fact that quail are more susceptible to human origin H7N9 infection may elucidate the preference of H7N9 for α 2,6 receptors *in vivo*. In addition, H7N9 experimental infection in ferrets have showed transmission through contact in 1 of 3 animals (Watanabe et al. 2013), indicating a greater pandemic potential of the H7N9 virus.

In conclusion, any of the poultry species studied showed to be potential reservoir and vector of H7N9 virus, especially quail and in a lesser extent chickens and Muscovy ducks. Control of H7N9 is complicated by the lack of disease signs in poultry. In the case of H7N9 surveillance, OS swab testing could be used as a unique tool for successful virus detection in active H7N9 surveillance in quail, Muscovy ducks and chickens, as it has been assessed for other avian species in which pathogenesis is still poorly understood (Bertran et al. 2013, Jones et al. 2014, Bertran et al. 2011).

Acknowledgment

The authors are grateful to Ramón Cedó for providing the quail and Muscovy ducks and to Dr. Inmaculada Casas from CNM (ISCIH) in Madrid for viral strain isolation and provision.

References

- BERTRAN K, DOLZ R, BUSQUETS N, GAMINO V, VERGARA-ALERT J, CHAVES AJ, RAMIS A, ABAD FX, HOFLE U, MAJO N** (2013) Pathobiology and transmission of highly and low pathogenic avian influenza viruses in European quail (*Coturnix c. coturnix*). *Vet Res*, 44:23.
- BERTRAN K, PEREZ-RAMIREZ E, BUSQUETS N, DOLZ R, RAMIS A, DARJI A, ABAD FX, VALLE R, CHAVES A, VERGARA-ALERT J.** (2012): Pathogenesis and transmissibility of highly (H7N1) and low (H7N9) pathogenic avian influenza virus infection in red-legged partridge (*Alectoris rufa*). *Vet Res*, 42:24.
- BUSQUETS N, ABAD FX, ALBA A, DOLZ R, ALLEPUZ A, RIVAS R, RAMIS A, DARJI A, MAJO N.** (2010) Persistence of highly pathogenic avian influenza virus (H7N1) in infected chickens: feather as a suitable sample for diagnosis. *J Gen Virol.*, 91:2307-2313.
- CAPUA I, ALEXANDER DJ** (2010) The challenge of avian influenza to the veterinary community. *Avian Pathol*, 35:189-205.
- COSTA T, CHAVES AJ, VALLE R, DARJI A, VAN RIEL D, KUIKEN T, MAJO N, RAMIS A** (2012) Distribution patterns of influenza virus receptors and viral attachment patterns in the respiratory and intestinal tracts of seven avian species. *Vet Res*, 43:28.
- ECDC** (2014) The Communicable Disease Threat Report, European Centre for Disease Prevention and Control In *Book The Communicable Disease Threat Report, European Centre for Disease Prevention and Control* (Editor ed.^eds.), vol. Week 27,. City.
- GAO R, CAO B, HU Y, FENG Z, WANG D, HU W, CHEN J, JIE Z, QIU H, XU K,** (2013) Human infection with a novel avian-origin influenza A (H7N9) virus. *N Engl J Med*, 368:1888-1897.
- JONES JC, SONNBERG S, KOCER ZA, SHANMUGANATHAM K, SEILER P, SHU Y, ZHU H, GUAN Y, PEIRIS M, WEBBY RJ, WEBSTER RG** (2014) Possible role of songbirds and parakeets in transmission of influenza A(H7N9) virus to humans. *Emerg Infect Dis*, 20:380-385.
- KWON TY, LEE SS, KIM CY, SHIN JY, SUNWOO SY, LYOO YS** (2010) Genetic characterization of H7N2 influenza virus isolated from pigs. *Vet Microbiol*, 153:393-397.
- LAM TT, WANG J, SHEN Y, ZHOU B, DUAN L, CHEUNG CL, MA C, LYCETT SJ, LEUNG CY, CHEN X.** (2013) The genesis and source of the H7N9 influenza viruses causing human infections in China. *Nature*, 502:241-244.
- LIU D, SHI W, SHI Y, WANG D, XIAO H, LI W, BI Y, WU Y, LI X, YAN J** (2014) Origin and diversity of novel avian influenza A H7N9 viruses causing human infection: phylogenetic, structural, and coalescent analyses. *Lancet*, 381:1926-1932.

LIU J, XIAO H, WU Y, LIU D, QI X, SHI Y, GAO GF (2014) H7N9: a low pathogenic avian influenza A virus infecting humans. *Curr Opin Virol* 2014, 5:91-97.

MARCHE S, CLAES G, VAN BORM S, VANGELUWE D, VAN DEN BERG T, LAMBRECHT B (2012) Different replication profiles in specific-pathogen-free chickens of two H7 low pathogenic avian influenza viruses isolated from wild birds. *Avian Dis*, 56:959-965.

MUNDT E, GAY L, JONES L, SAAVEDRA G, TOMPKINS SM, TRIPP RA (2009) Replication and pathogenesis associated with H5N1, H5N2, and H5N3 low-pathogenic avian influenza virus infection in chickens and ducks. *Arch Virol*, 154:1241-1248.

PANTIN-JACKWOOD MJ, MILLER PJ, SPACKMAN E, SWAYNE DE, SUSTA L, COSTA-HURTADO M, SUAREZ DL (2014) Role of poultry in the spread of novel H7N9 influenza virus in China. *J Virol*, 88:5381-5390.

SHI Y, ZHANG W, WANG F, QI J, WU Y, SONG H, GAO F, BI Y, ZHANG Y, FAN Z. (2013) Structures and receptor binding of hemagglutinins from human-infecting H7N9 influenza viruses. *Science*, 342:243-247.

VAN RIEL D, LEIJTEN LM, DE GRAAF M, SIEGERS JY, SHORT KR, SPRONKEN MI, SCHRAUWEN EJ, FOUCHIER RA, OSTERHAUS AD, KUIKEN T. (2013) Novel avian-origin influenza A (H7N9) virus attaches to epithelium in both upper and lower respiratory tract of humans. *Am J Pathol*, 183:1137-1143.

WATANABE T, KISO M, FUKUYAMA S, NAKAJIMA N, IMAI M, YAMADA S, MURAKAMI S, YAMAYOSHI S, IWATSUKI-HORIMOTO K, SAKODA Y, (2013) Characterization of H7N9 influenza A viruses isolated from humans. *Nature*, 501:551-555.

YANG S, CHEN Y, CUI D, YAO H, LOU J, HUO Z, XIE G, YU F, ZHENG S, YANG Y. (2013) Avian-origin influenza A(H7N9) infection in influenza A(H7N9)-affected areas of China: a serological study. *J Infect Dis*, 209:265-269.

YU H, COWLING BJ, FENG L, LAU EH, LIAO Q, TSANG TK, PENG Z, WU P, LIU F, FANG VJ (2013) Human infection with avian influenza A H7N9 virus: an assessment of clinical severity. *Lancet*, 382:138-145.